



The PerCutaneous Compression Plate (PCCP™) in the treatment of trochanteric hip fractures in elderly patients

Hocine BENSATI, Jean-Michel LAFFOSSE, Gérard GIORDANO, Charles DAO, Philippe CHIRON, Jean PUGET

From the Centre Hospitalier Universitaire Rangueil, Toulouse, France

We carried out a prospective study to assess the value of mini-invasive osteosynthesis with the PerCutaneous Compression Plate (PCCP™) in the treatment of trochanteric hip fractures in elderly patients. Sixty five consecutive patients were included, with an average age at surgery of 84.2 years (range: 63 to 99), with more than 93% ASA 2, 3 or 4 patients. No peri-operative complications were noted. All but two patients were ambulatory with weight bearing two days after operation. The postoperative blood transfusion rate was only 25%. No patient was lost to follow-up. We noted 11 deaths (17%) at the end of follow-up (5 during hospitalisation and 6 during the first 9 months). The re-operation rate was 4.5%. Osteosynthesis with the PCCP™ allows for decreased intraoperative bleeding and minimises injury to muscle and tendon structures. The stability and quality of the construct enable early recovery of patients while limiting morbidity for this type of fracture.

Keywords: mini-invasive; osteosynthesis; elderly; trochanteric fracture.

INTRODUCTION

Trochanteric hip fractures represent a society issue because of their human, social and economic repercussions (24), which will keep increasing with ageing of the population and the increasing incidence of this type of fracture.

The aim of all methods of treatment is to get people back on their feet as early as possible so

as to minimise complications caused by the recumbent position in this already fragile population. It is also desirable to use an operating procedure with the lowest possible morbidity rate. The concept of minimally invasive surgery therefore embodies the perfect technique for this indication.

The PerCutaneous Compression Plate (PCCP™) is a recent improvement in implants for treatment of these types of fractures, and a significant addition to the surgical armamentarium for internal fixation of proximal femoral fractures.

MATERIAL AND METHODS

We carried out a prospective study to assess the early results of internal fixation of trochanteric fractures using the PCCP™ in elderly patients. We included fractures of

- Hocine Bensati, MD, Fellow.
- Jean-Michel Laffosse, MD, Resident.
- Gérard Giordano, MD, Orthopaedic Surgeon.
- Charles Dao, MD, Resident.
- Philippe Chiron, MD, Professor.
- Jean Puget, MD, Professor.

Service d'Orthopédie et de Traumatologie, CHU Rangueil, 1, avenue Jean Paulhès TSA 50032, 31059 Toulouse Cedex 9, France.

Correspondence: Dr Jean-Michel Laffosse, 2, rue Baronie, 31000 Toulouse, France.

E-mail: jean-michel.laffosse@wanadoo.fr.

© 2006, Acta Orthopædica Belgica.



Fig. 1. — View of the two skin incisions at the end of the procedure.

the trochanteric region with 2 fragments (type 31-A1 in the AO classification), and with multiple fragments (type 31-A2 in the AO classification). Subtrochanteric fractures (type 31-A3 in the AO classification), fractures which could not be reduced by external manoeuvres on the orthopaedic table, and fractures in patients under 60 following high-energy trauma were excluded from the study.

Sixty five consecutive patients were included in the study between December 2003 and February 2005. Their average age at the time of surgery was 84.2 years (range : 63 to 99). There were 53 women and 12 men. All patients were operated within 24 hours of injury, except those requiring prior interruption of anticoagulant or antiplatelet treatment. The type of anaesthesia and the comorbidities represented by the ASA score were specified. The Singh Index (22) was assessed on the opposite, non-fractured hip by means of an AP radiograph of the pelvis.

Internal fixation using the PCCP™ was carried out using the technique described by Gottfried in 2000 (10). The fracture was reduced on the orthopaedic table in the supine position, with fluoroscopy control, prior to osteosynthesis. Inability to reduce the fracture using external manoeuvres was considered a contraindication for this type of implant. Two 2 to 3cm incisions (fig 1) were sufficient to place the plate. No drainage system was used. The Department's rehabilitation protocol consisted of getting the patient on his/her feet as soon as possible within 24 to 48 hours after the operation, with full weight bearing when the medial femoral buttress permitted, and limited to 50% of body weight in other cases. Intraoperative complications were noted, as was

the duration of the operation, of fluoroscopy (excluding the reduction time). The position of the cervical screws was assessed in radiographs taken immediately after operation. It was considered excellent when the proximal cervical screw was in the centre of the head (fig 2a), on the anteroposterior (AP) and mediolateral (ML) view, good when the two screws were located on either side of the centre (fig 2b), and poor when the proximal screw was located in the proximal third of the head (fig 2c).

The overall blood loss was calculated postoperatively using a standard method of calculation (7); the number of red blood cells units transfused during the period of hospitalisation, as well as postoperative complications and duration of hospital stay were also recorded.

All patients were reassessed at 45 days, 3 and 6 months with a clinical examination and radiological assessment (AP and ML views of the operated hip and AP view of the pelvis).

RESULTS

No patient was lost to follow-up. Average follow-up was 12 months (range : 9 to 16). More than 93% of patients (61/65) were ASA 2, 3 or 4 (fig 3). Spinal anaesthesia was carried out in 80% of cases. In the large majority of cases, the fractures were uncomplicated with little fragmentation (fig 4). In 98% of cases (64/65), patients presented marked osteoporosis, with a Singh Index grade 1, 2 or 3. The average duration of the operation "skin to skin" was 35 min (range : 25 to 50) with an average duration of fluoroscopy of 60 seconds (range : 40 to 85). No perioperative complications were recorded.

The position of the screws was considered excellent in 44 cases (68%), good in 15 cases (23%) and poor in 6 cases (9%). The mean volume of blood loss was calculated to be 308 ml (range : 56 to 1250). Postoperative blood transfusion was necessary in only 16 cases (25%), with on average 0.8 ± 1.1 units (0-4) per patient for the entire series. All patients were on their feet between the 2nd and 3rd day after the operation, with the exception of two patients, due to their general condition. Average duration of hospital stay was 14.8 days (range : 5 to 21).

We recorded the number of postoperative complications. Five patients died in the early postoperative period, before the end of the 3rd week, and

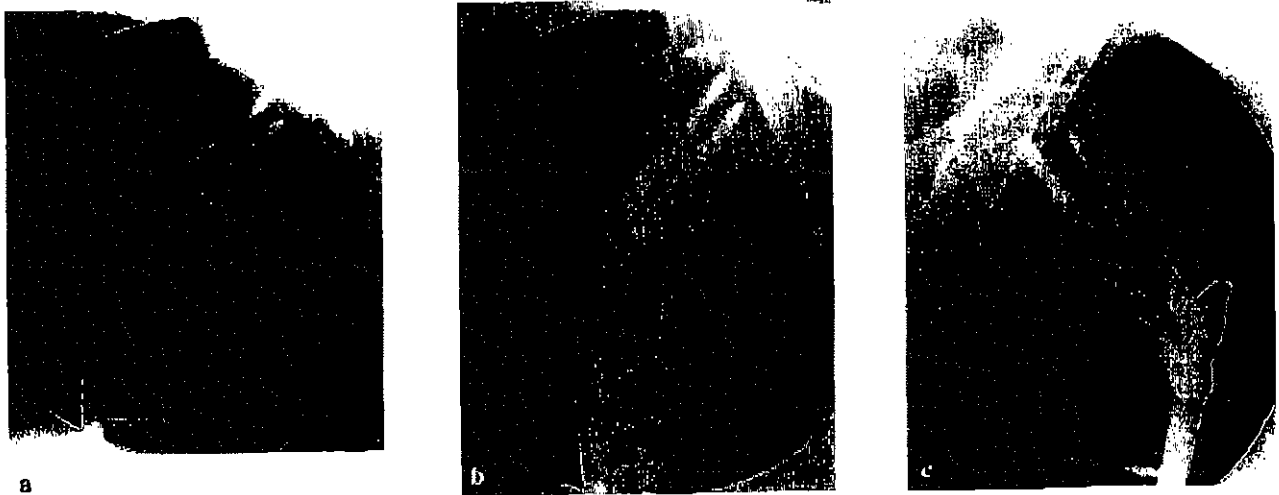


Fig. 2. — Centring quality of the cervical screws ; a. excellent centring ; b. good centring ; c. poor centring

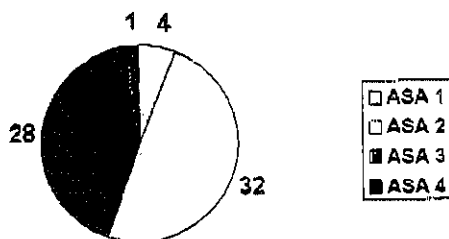


Fig. 3. — Distribution of the ASA scores

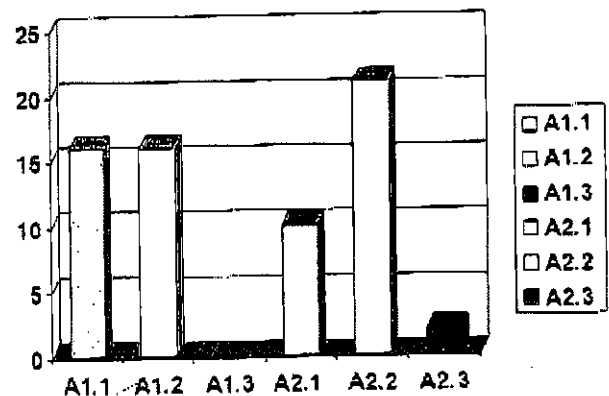


Fig. 4. — Distribution of the AO fracture types

six others during the first 9 months, i.e. a total of 11 deaths (17%). Ten urinary infections were diagnosed, one of which caused septic shock followed by death of the patient. Five cases of heel sores and two cases of deep vein thrombosis were recorded.

All fractures were found to have healed when the patients were seen at the clinic 3 months after operation. During the radiological follow-up, screw cut-out was noted in three cases (4.5%), of which two required revision surgery. The first one was treated by implanting a Puget-type reconstruction prosthesis. In the second case, removal of the proximal screw in the neck of the femur was sufficient. The third patient died before correction could take place. Fracture impaction less than 10 mm occurred, without any functional repercussions. A summary of all clinical and radiological results can be found in table I.

DISCUSSION

Fractures of the proximal femur, including fractures affecting the trochanteric region, have become a public health problem. Owing to aging of the population, we have to operate on ever more elderly patients who sometimes present with significant comorbidities. However, the indication for surgery is indisputable, given the considerable morbidity and mortality related to prolonged confinement to bed (5). There is a wide array of operative treatments available for this type of fractures.

Osteosynthesis using a screw plate of the dynamic hip screw (DHS)-type is considered to be

THE PERCUTANEOUS COMPRESSION PLATE

317

Table I. — Preoperative and postoperative clinical and radiological data

PCCPT™	
Number of patients	65
Age	84.2 (63-99)
Gender F/M	53 / 12
ASA score 1/2/3/4	4/32/28/1
AO Fracture Types A1/A2	32/33
Singh index 1/2/3/4/5	25/25/12/1/2
Spinal anaesthesia / general anaesthesia	52/13
Transfusion during hospitalisation (units)	0.8 ± 1.1 (0-4)
Average estimated blood loss (ml)	308 ± 233 (56-1250)
General postoperative complications :	
– death : during hospitalisation / at the end of follow-up	5 / 11
– other complications	urinary infections : 10, sore : 5, DVT : 2
Mechanical complications :	
– Screw cut-out	3 (4.5 %)
– Impaction	10 (15.4 %)

F = female, M = male, ASA = American Association of Anaesthesiology.

the "gold-standard" (17) for intertrochanteric fractures type 31-A1 and 31-A2 in the AO classification. The majority of studies have not shown any significant difference in terms of clinical and radiological results in this indication between the DHS and intramedullary systems (8, 20). The latter carry a risk of femoral diaphyseal fractures ; for this reason, some authors (8) advise against routine use of this type of procedure in stable fractures and suggest using it for unstable, multi-fragment fractures, and for subtrochanteric fractures (2, 23).

The cut-out rate of cervical screws and revision surgery was 4.5% in our series, concurring with other PCCPT™ series (13, 18, 19), in comparison with 4 to 10% for other types of osteosynthesis in the literature (1, 15). This low failure rate may be related to the presence of two cervical screws, which increases torsional stability (10, 11) while allowing for impaction of the fracture site. The stability allows for immediate weight bearing in the case of a stable fracture, with 100% consolidation at 3 months. However, the shaft plate provides an assembly which avoids the excessive rigidity achieved with the Gamma nail™, which can cause a fracture of the femur (8). The rate of general complications observed in our study is comparable to

that of other authors (3, 8-10, 19, 21), in particular the number of deaths occurring during the first 6 months after operation. The follow-up of our study is short but nevertheless sufficient to assess the death rate.

Osteosynthesis with the PCCPT™ is associated with less perioperative blood loss (6, 12, 13). This reduces the rate of allogeneic blood transfusions (18) during the postoperative period in comparison to other series in the literature studying the results of DHS and the Gamma nail™. Bierbaum *et al* (4) insisted on the morbidity of postoperative allotransfusions : significantly larger number of infections (in particular urinary), excessive volaemia, increased hospital stay, to which other complications can be added such as infections, fever, urticaria, haemostatic accidents, etc. In addition, it has been demonstrated that the maximum benefit from the operation is obtained in the postoperative period when a subnormal haematocrit is restored as early as possible. This enables a specific rehabilitation programme (4) to be started with patients being rapidly ambulatory. The smaller amount of bleeding during the operation decreases the need for allogeneic blood transfusion, which remains risky and costly.

McConnel *et al* (16) mentioned injury to the *gluteus medius* caused by reaming when using intramedullary devices; on the other hand, osteosynthesis with a standard DHS requires a wider detachment of the *vastus lateralis* muscle, a source of significant haematomas in the postoperative period (6). Minimally invasive surgery with percutaneous insertion of a plate beneath the *vastus lateralis* without damaging the *gluteus medius* contributes to earlier, more rapid and more effective rehabilitation (12, 14).

However, some authors (13) found that a longer operation time was required for the percutaneous insertion of these implants, which might appear to increase the invasiveness of the surgery. This may however be related to the learning curve, because other authors, on the contrary, have found a shorter operation time (6, 18). This type of osteosynthesis therefore permits rapid recovery of ambulation, which is also the case with other types of internal fixation, but with the added benefit of a less invasive surgical technique.

CONCLUSION

Internal fixation of both stable and unstable intertrochanteric fractures (31-A1 and 31-A2 in AO classification) with the PCCP™ is reliable. The operating technique is reproducible after a short learning curve. The decrease in overall intraoperative bleeding and in the need for allogeneic transfusion, the minimal injury to muscle and tendon structures, and the stability of the assembly enable early recovery of patients with minimal postoperative morbidity. The PCCP™ thus fulfils the concept of minimally invasive surgery and should be included in the armamentarium for the surgical treatment of intertrochanteric fractures in fragile, elderly patients. These conclusions should nevertheless be confirmed by a comparative randomised prospective study.

REFERENCES

1. Ahrengart L, Törnkvist H, Fornander P *et al*. A randomized study of the compression hip screw and gamma nail in 426 fractures. *Clin Orthop* 2002; 401: 209-222.
2. Baumgaertner MR, Curtin SL, Lindskog DM. Intramedullary versus extramedullary fixation for the treatment of intertrochanteric hip fractures. *Clin Orthop* 1998; 348: 87-94.
3. Berkenbaum I, El Banna S. Osteosynthesis of trochanteric fracture with percutaneous compression plate (P.C.P.). *Rev Med Brux* 2004; 25: 40-46.
4. Bierbaum BE, Callaghan JJ, Galante JO *et al*. An analysis of blood management in patients having a total hip or knee arthroplasty. *J Bone Joint Surg* 1999; 81-A: 2-10.
5. Bonneville P, Féron JM. Les fractures des sujets âgés de plus de 80 ans. Symposium SOFCOT 2002. *Rev Chir Orthop* 2003; 89: 25129-182.
6. Brandt S, Lefever S, Janzing H *et al*. Percutaneous compression plating (PCCP™) versus the dynamic hip screw for peritrochanteric hip fractures: preliminary results. *Injury* 2002; 33: 413-418.
7. Brecher ME, Monk T, Goodnough LT. A standardized method for calculating blood loss. *Transfusion* 1997; 37: 1070-1074.
8. Butt MS, Krikler SJ, Nafie S, Ali MS. Comparison of dynamic hip screw and gamma nail: a prospective, randomized, controlled trial. *Injury* 1995; 26: 615-618.
9. Dujardin FH, Benez C, Pette G *et al*. Prospective randomized comparison between a dynamic hip screw and a mini-invasive static nail in fractures of the trochanteric area: preliminary results. *J Orthop Trauma* 2001; 15: 401-406.
10. Gotfried Y. Percutaneous compression plating of intertrochanteric hip fractures. *J Orthop Trauma* 2000; 14: 490-495.
11. Gotfried Y, Rotem A. Biomechanical evaluation of the percutaneous compression plating system for hip fractures. *J Orthop Trauma* 2002; 16: 644-50.
12. Janzing H, Hauben B, Brandt S *et al*. The Gotfried PerCutaneous Compression Plate versus the Dynamic Hip Screw in the treatment of peritrochanteric hip fractures: minimal invasive treatment reduces operative time and postoperative pain. *J Trauma* 2002; 52: 293-298.
13. Kosygan K, Mohan R, Newman R. The Gotfried percutaneous compression plate compared with the conventional classic hip screw for the fixation of intertrochanteric fractures of the hip. *J Bone Joint Surg* 2002; 84-B: 19-22.
14. Laufer Y, Lahav M, Lenger R, Sprecher E. Functional recovery following peritrochanteric hip fractures fixated with the Dynamic Hip Screw vs. the percutaneous compression plate. *Scientific World Journal* 2005; 19: 221-229.
15. Madsen JE, Naess L, Aune AK *et al*. Dynamic hip screw with trochanteric stabilizing plate in the treatment of unstable proximal femoral fractures: a comparative study with the Gamma nail and compression hip screw. *J Orthop Trauma* 1998; 12: 241-248.

16. McConnel T, Tornetta III P, Benson E, Manuel J. Gluteus medius tendon injury during reaming for gamma nail insertion. *Clin Orthop* 2003 ; 407 : 199-202.
17. Parker MJ, Pryor GA. Gamma versus DHS nailing for extracapsular femoral fractures. Meta-analysis of ten randomised trials. *Int Orthop* 1996 ; 20 : 163-168.
18. Peyser A, Weil Y, Brocke L et al. Percutaneous compression plating versus compression hip screw fixation for the treatment of intertrochanteric hip fractures. *Injury* 2005 ; 36 : 1343-1349.
19. Peyser A, Weil Y, Liebergall M, Mosheiff R. Percutaneous compression plating for intertrochanteric fractures. Surgical technique, tips for surgery, and results. *Oper Orthop Traumatol* 2005 ; 17 : 158-177.
20. Saudan M, Lubbeke A, Sadowski C et al. Pertrochanteric fractures : is there an advantage to an intramedullary nail ? A randomized, prospective study of 206 patients comparing the dynamic hip screw and proximal femoral nail. *J Orthop Trauma* 2002 ; 16 : 386-393.
21. Schipper IB, Steyerberg EW, Castelein RM et al. Treatment of unstable trochanteric fractures. Randomised comparison of the gamma nail and the proximal femoral nail. *J Bone Joint Surg* 2004 ; 86-B : 86-94.
22. Singh M, Nagrath A, Maini P. Changes in trabecular pattern of the upper end of the femur as an index of osteoporosis. *J Bone Joint Surg* 1970 ; 52-A : 457-467.
23. Utrilla AL, Reig JS, Munoz FM, Tufanisco CB. Trochanteric gamma nail and compression hip screw for trochanteric fractures : a randomized, prospective, comparative study in 210 elderly patients with a new design of the gamma nail. *J Orthop Trauma* 2005 ; 19 : 229-233.
24. Willig R, Keinanen-Kiukaantemi S, Jalovaara P. Mortality and quality of life after trochanteric hip fracture. *Public Health* 2001 ; 115 : 323-327.